


#niwop



video.wh.com

Now at  
your dealer  
or [wh.com](http://wh.com)



# NIWOP:

The systematic and  
evidence-based  
workflow



Implantology  
without **Periodontology** is  
like **Yin** without **Yang**.



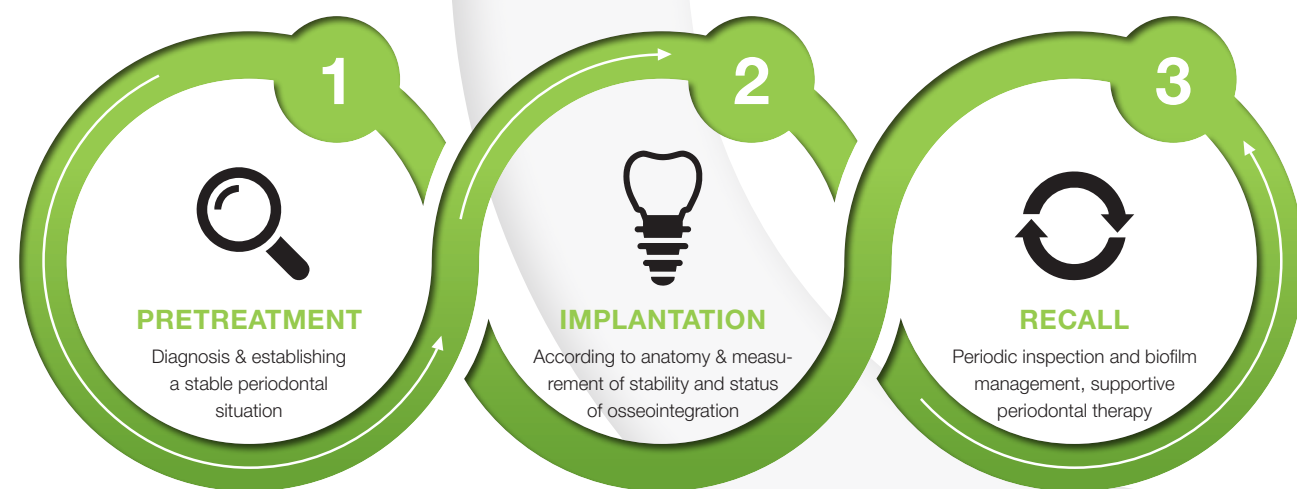
# No Implantology without Periodontology – NIWOP

## Optimal periodontal conditions for successful implantation

**Some things do belong together: just as Yin needs the Yang, implantology needs periodontology. W&H presents »No Implantology without Periodontology«, NIWOP for short, a systematic and evidence-based workflow for a sound and healthy tissue situation around the implant.**

Implant care can significantly improve quality of life after tooth loss (1, 2). The long-term prognosis is generally good, but biological complications are common (3). Periimplantitis and its preliminary stage mucositis occur in a substantial proportion of patients (4). As is the case for periodontitis and gingivitis, oral biofilm is the main cause (5, 6). This microbial biocoenosis can also encourage the development of severe systemic diseases in the event of pathological changes, such as endocarditis and inflammatory bowel diseases (7).

The only difference in the microbial flora in periodontitis and periimplantitis is in the detail (8). Compared to healthy conditions, the quantity and aggressiveness of the pathogenic microorganisms change in both diseases (5, 6). Bone loss around implants is generally more rapid and leads to more extensive defects than when it occurs around teeth (9). Accordingly, preventive care is advised even before an implant.



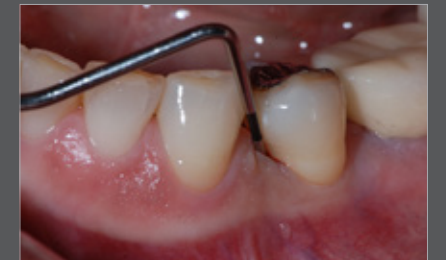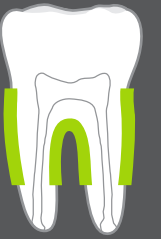## 1. Pretreatment

### Determining risks – providing periodontal treatment

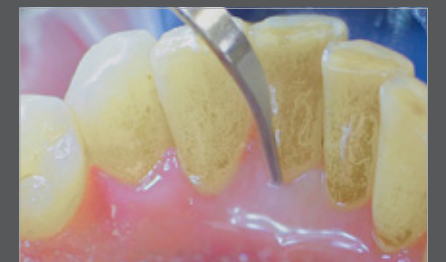Periodontitis is a key risk factor for peri-implant inflammation. This means untreated periodontitis patients have an increased risk of peri-implant inflammation through to implant loss (10). The risk is also higher when patients who are initially treated are not included in a supportive periodontitis treatment/recall programme (11).

Leading periodontologists therefore recommend carrying out a screening procedure before implant, for example using the Periodontal Screening Index (PSI) / Periodontal Screening and Recording (PSR) (Fig. 1) (12). Bleeding on probing and pocket depths are determined at selected positions. An extensive check of the periodontal status should be carried out if the results are abnormal (13). Taking the medical history carefully including previous systemic exposure is also important (13). This provides important information about increased risk of inflammation, for example in patients with diabetes that is not being optimally managed (14). Patients should be informed of the risks relating to implants.

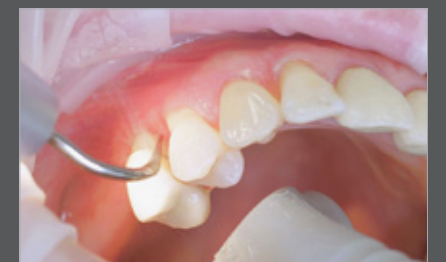Where necessary, initial periodontal treatment is carried out. First, professional tooth cleaning creates healthy gingival conditions. In this procedure, calculus (Fig. 2) and biofilm are removed as far as the gingival sulcus. In combination with careful instruction on oral hygiene, the patient has the basis for long-term freedom from inflammation (15). Removal of subgingival coatings (debridement) is carried out using sonic or ultrasound devices and special periodontal tips as initial periodontal treatment (Fig. 3). Manual instruments can also be used. Further surgical and/or regenerative measures may be necessary depending on the situation.



**Fig. 1 WHO probe**  
Regular periodontal screening is part of the basic diagnosis, particularly when an implant is planned.  
(Photo: Dr. Kenji Hosoya)



**Fig. 2 Tigon+ with 3U**  
Calculus removal using an ultrasound is a key part of professional tooth cleaning.



**Fig. 3 Proxeo air scaler with 1AP**  
If marginal periodontitis is diagnosed, the initial debridement can be carried out very efficiently with an air scaler.



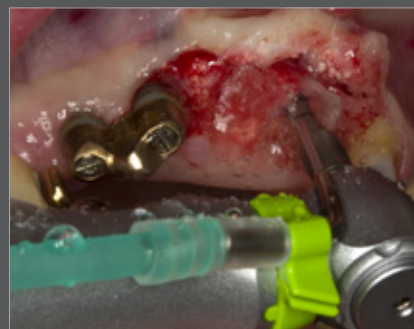## 2. Implantation

### Proactive implants

If the patient has received good preventive treatment and where necessary has received preliminary periodontal treatment, implant care can be planned. A suboptimal implant-supported prosthetic increases the likelihood of biofilm forming (16). In order to avoid this, the correct implant position, sufficient distances from adjacent teeth and an ideal axial alignment should be taken into account during the planning phase.

In order to ensure predictable and stable implant care, it is also necessary to prepare the implant bed using suitable methods and the right hardware. This can be achieved using high-performance implantology motors in combination with surgical contra-angle handpieces (Fig. 4). Low speed and an ample supply of sterile cooling fluid are essential during preparation (17). Otherwise, the bones can overheat and affect the healing process.

Alternatively, the implant bed can be prepared with piezosurgical systems, for which special sets of instruments are available (18). Bones can be prepared in a gentle yet highly effective manner using other special instruments. Indications include alveolar ridge splitting, surgical tooth removal and the preparation of bone blocks or lateral windows for augmentation (19). Highly developed piezosurgical devices are also minimally invasive in soft tissue.



**Fig. 4 Implantmed and WS-56**

Ensure optimal torque and safe cooling, with an implantology motor and a surgical contra-angle handpiece.  
(Photo: Dr. Karl-Ludwig Ackermann)

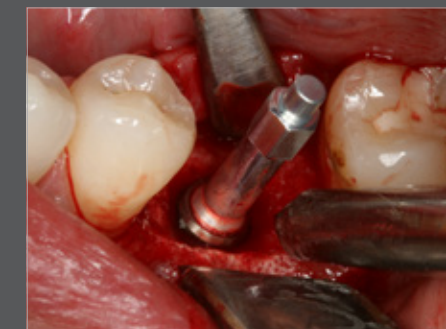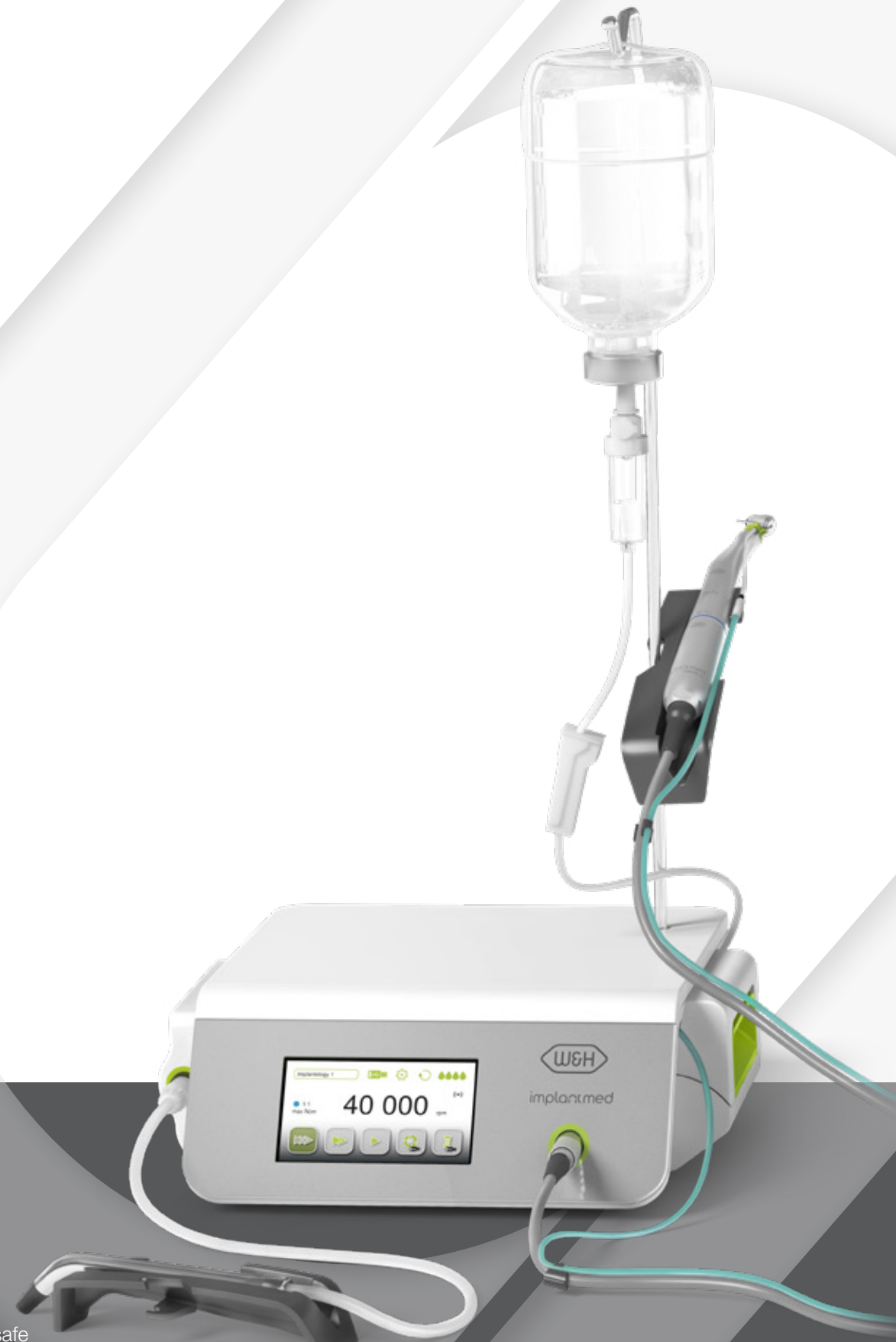## 2. Stability measurement



### Stability measurement and bone surgery

Once the implant that has been screwed into its final position, the primary stability can safely and precisely be determined using a resonance frequency analysis (RFA) (Fig. 5). The technology is either available separately or as an optional module in an implantology motor. If the Implant Stability Quotient (ISQ) measured is 66 or higher, early intervention is possible, and if it is over 70, treatment can be provided immediately (20).

An exposure protocol based on the ISQ value improves the prognosis of treatment. Simply measuring the screwing resistance, however, does not provide the same level of clinical safety (21). If reduced ISQ values are measured after the implant has been inserted, a two-phase protocol is generally chosen. After exposure, a new measurement can then be used to determine whether the osseointegration was successful (secondary stability) and loading will be predictable at this point (22).



**Fig. 5 Osstell ISQ module**

Resonance frequency analysis (Osstell ISQ module) can be used to determine whether the implant can already be prosthetically loaded.  
(Photo: Dr. Jörg Neugebauer)

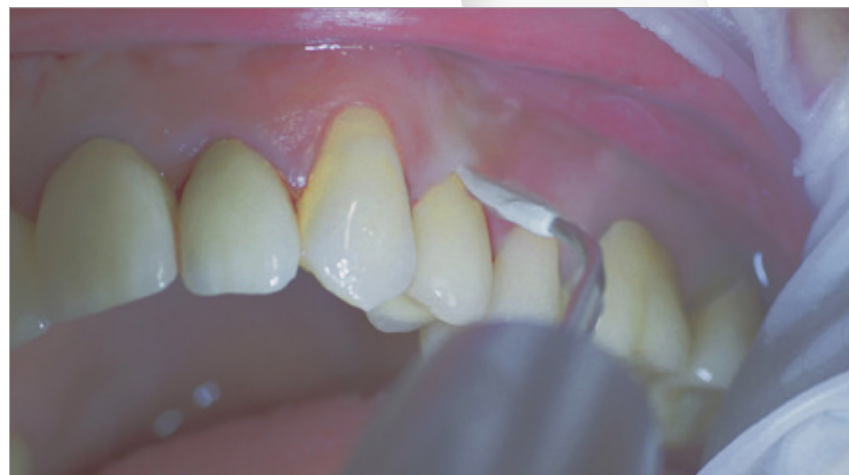### 3. Recall

#### Peri-implant aftercare

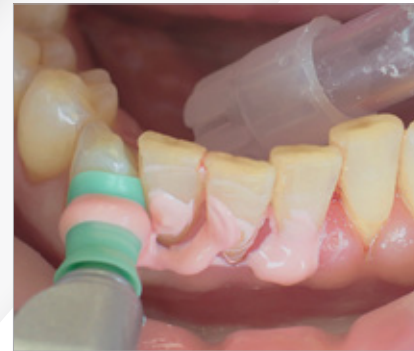Experts recommend treatment immediately after the initial occurrence of symptoms of inflammation to avoid periimplant bone loss from the start (23). Mucositis occurs in almost half of all implants, and since patients often have several implants it occurs in a high percentage of patients (24).

The prophylactic or periodontal recall established after the implant is inserted should therefore be continued (23, 25). Domestic oral hygiene is carefully tailored to the new prosthesis and patients are accordingly instructed on this (26). In combination with professional biofilm management (Fig. 6), good preventative efficacy can be achieved in this way (27).

The risk of periimplantitis decreases from 43.9 percent (no recall) to 18 percent if a patient receives a recall appointment carried out carefully each year, in other words by more than half (28). Ultrasound systems with special instruments that do not affect the materials are suitable for this, such as those made of PEEK (Fig. 7) or appropriate manual instruments (29).



**Fig. 7 Tigon+ with 1l**  
Implants and suprastructures are routinely cleaned, for example using ultrasound devices and special plastic instruments.



**Fig. 6 Proxeo with polishing cup**  
Rotary cleaning with prophylaxis polishing cups and brushes removes biofilm and deposits.

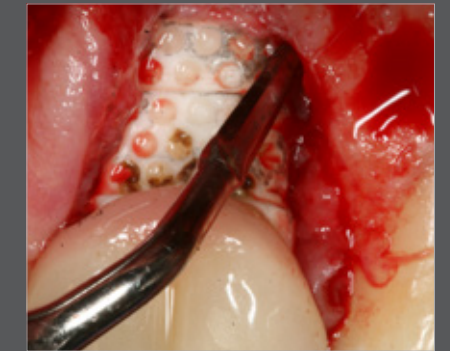
### 3. Periimplantitis

#### Treating periimplantitis

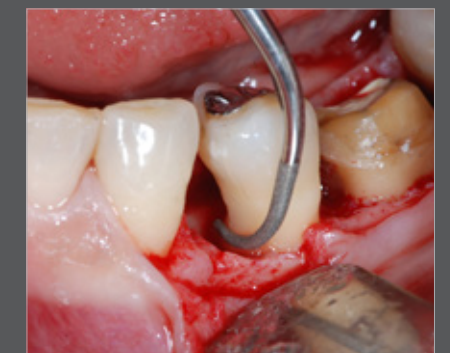Peri-implant bone loss can develop even if good preventative care is provided, for example if the patient's oral hygiene is not sufficient. Most minimal defects should be treated in a non-surgical manner using peri-implant debridement (29). Mechanical removal of coatings using suitable ultrasound systems, where appropriate supported by Er:YAG lasers, antibacterial photodynamic treatment (aPDT), air polishing or treatment with local or systemic antibiotics, is showing promising results (29).

If closed treatment is no longer possible, the defect must be surgically exposed and carefully decontaminated. This is carried out following flap preparation by removing inflamed tissue and cleaning the surface of the implant, for example using ultrasound or piezosurgical systems (Fig. 8). Measures designed to regenerate the bone carried out after this procedure are successful (30). Special piezosurgical instruments are available for the surgical treatment of periodontal defects (Fig. 9).

After treatment, the patient is once again intensively trained in oral hygiene and made aware of the need for continuous recall. If necessary, the frequency can be selected to be higher than previously in line with periodontal aftercare. If biofilm management is carried out consistently, the implantological results can remain stable for several years even after the periodontitis, mucositis or periimplantitis has healed (25, 31).



**Fig. 8 Piezomed with EX2**  
Debridement can be carried out with a piezosurgical instrument as part of open periimplantitis treatment. (Photo: Dr. Jörg Neugebauer)



**Fig. 9 Piezomed with P2RD/LD**  
Periodontal defects can also be treated effectively through surgery using a piezosurgical system. (Photo: Dr. Kenji Hosoya)



Bibliography

No  
Implantology without  
Periodontology

**W&H Dentalwerk Bürmoos GmbH**

Ignaz-Glaser-Straße 53, Postfach 1

5111 Bürmoos, **Austria**

**t** +43 6274 6236-0

**f** +43 6274 6236-55

office@wh.com

**wh.com**

Pictures are for illustrative purposes only. Additional equipment  
and accessories are not included with the item.

20478 AEN Rev. 004 / 23.07.2019  
Subject to alterations